

Pathological and parasitological aspects of the peacock (*Pavo cristatus*) infection by *Tanaisia (Paratanaisia) bragai*¹

Rafael C. Costa², Natália A. Ambrósio³, Bruno A. Soares³, Pedro S. Bezerra Júnior²,
Thales A. Barçante⁴, Priscilla R. Barrios³ and Joziana M.P. Barçante^{3*}

ABSTRACT.- Costa R.C., Ambrósio N.A., Soares B.A., Bezerra Jr P.S., Barçante T.A., Barrios P.R. & Barçante J.M.P. 2015. **Pathological and parasitological aspects of the peacock (*Pavo cristatus*) infection by *Tanaisia (Paratanaisia) bragai*.** *Pesquisa Veterinária Brasileira* 35(5):466-469. Setor de Medicina Veterinária Preventiva, Departamento de Medicina Veterinária, Universidade Federal de Lavras, Campus Universitário, Cx. Postal 3037, Lavras, MG 37200-000, Brazil. E-mail: joziana@dmv.ufla.br

Trematodes belonging to the family Eucotylidae, including *Tanaisia (Paratanaisia) bragai* Santos, 1934, are parasites of the kidney and ureter that affect several species of domestic and wild birds. *Tanaisia bragai* is considered a low pathogenic parasite, but high worm burdens may determine clinical complications, including signs of apathy, weight loss, diarrhea and death. This paper describes the first report of infection by *T. bragai* in peacocks (*Pavo cristatus*), which constitutes a new host record and offers data on the lesions associated to this parasitism, although the degree of pathogenicity and parasite load may be considered mild. These birds did not exhibit clinical signs of parasitism. The macroscopic exam revealed discreet yellow spots on the liver. In the histological sections of the kidney, specimens of *T. bragai* were found in the collecting ducts, which were markedly dilated, with a thickened wall. Other findings included a mild inflammatory reaction in the wall of the ducts (but sometimes absent), flattening of lining epithelial cells and small, multifocal points of calcification around the collecting ducts. The microscopic examination of the parasites revealed trematodes with an elongated body, well-developed sub terminal oral sucker, pharynx present, short esophagus, cecum somewhat undulating or not, with blind end, testes symmetrical, equatorial, irregular in shape or slightly lobed, vitelline fields extending in both pre-ovarian and post ovarian fields, uterus very long, intercecal or sometimes overlapping the cecum and containing large quantities of eggs. The present findings suggest the need for further diagnostic studies on the prevalence of this trematode in peacocks as well as pathologic studies for the determination of the potential pathogenicity of this parasite in this species of bird. Moreover, infected peacocks could serve as carriers of *T. bragai* to be transferred to other bird species, thereby contributing to the dispersion of the parasite.

INDEX TERMS: *Tanaisia (Paratanaisia) bragai*, trematode, kidney, exotic bird, peacock, *Pavo cristatus*, pathology.

¹ Received on October 7, 2014.

Accepted for publication on February 27, 2015.

² Setor de Patologia Veterinária, Departamento de Medicina Veterinária, Universidade Federal de Lavras (UFLA), Cx. Postal 3037, Lavras, MG 37200-000, Brasil.

³ Setor de Medicina Veterinária Preventiva, Departamento de Medicina Veterinária, UFLA, Cx Postal 3037, Lavras, MG 37200-000, Brasil. *Corresponding author: joziana@dmv.ufla.br

⁴ Pontifícia Universidade Católica de Minas Gerais. Curso de Medicina Veterinária, Av. Cletus Francis Cox, Poços de Caldas, MG 37701-355, Brasil.

RESUMO.- [Aspectos patológicos e parasitológicos da infecção por *Tanaisia (Paratanaisia) bragai* em pavões (*Pavo cristatus*).] Os trematódeos da família Eucotylidae, incluindo *Tanaisia (Paratanaisia) bragai* Santos, 1934, são parasitos de rins e ureteres de várias espécies de aves domésticas e silvestres. *Tanaisia bragai* é considerada uma espécie pouco patogênica, mas que pode determinar complicações clínicas como apatia, perda de peso, diarréia e morte, quando em cargas parasitárias elevadas. No presen-

te trabalho, descreve-se o primeiro relato de *T. bragai* parasitando pavões (*Pavo cristatus* Linnaeus, 1758), incluindo os achados parasitológicos e patológicos associados à infecção. A ausência de sinais clínicos evidencia uma infecção moderada, na qual, ao exame macroscópico dos órgãos internos, verificou-se a presença de pequenas manchas amareladas no fígado. Ao exame histopatológico, foram verificados espécimes de *T. bragai* nos ductos coletores dos rins, que se apresentavam marcadamente dilatados e com adelgaçamento das paredes. Verificou-se também moderada reação inflamatória (por vezes ausente) na parede dos ductos e pequenos pontos de calcificação ao redor dos mesmos. No interior do órgão foram recuperados parasitos de corpo alongado, com ventosa oral subterminal e bem desenvolvida, ventosa acetabular, faringe, esôfago curto, cecos intestinais em fundo cego, testículos simétricos e equatoriais e irregulares, glândulas vitelínicas presentes nas regiões pré e pós-ovarianas, útero longo e contendo grande quantidade de ovos. O presente achado sugere a necessidade de novos estudos diagnósticos a fim de determinar a prevalência e a importância deste parasito para pavões. Além disso, os pavões demonstraram ser hospedeiros definitivos de *T. bragai*, podendo servir de fonte de infecção para o ambiente, contribuindo para a dispersão do parasito.

TERMOS DE INDEXAÇÃO: *Tanaisia* (*Paratanaisia*) *bragai*, trematode, rim, ave exótica, pavão, *Pavo cristatus*, patologia.

INTRODUCTION

Tanaisia (*Paratanaisia*) *bragai* (Freitas, 1959) is a digenetic trematode found in the kidney collecting ducts of different species of wild and domesticated birds (Brandolini et al. 1997, Kanev et al. 2002). This species has been identified in Central and South America, Asia and Oceania. In Brazil, *T. bragai* has been found in the following birds: chicken (*Gallus gallus domesticus*), pigeon (*Columba livia*), pheasant (*Phasianus colchicus*), helmeted Guineafowl (*Numida meleagris*), turkey (*Meleagris gallopavo*), white-eared parakeet (*Pyrrhura leucotis*), red-winged timamou (*Rhynchotus rufescens*), blue-winged macaw (*Propyrrhura maracana*) and ruddy ground dove (*Columbina talpacoti*) (Keller & Araujo 1992, Menezes et al. 2001, Mapeli et al. 2003, Pinto et al. 2004, Gomes et al. 2005, Luppi et al. 2007). Birds become infested by ingesting gastropods containing metacercariae. Infection is generally subclinical, with more evident signs in birds with a high parasite burden (Greve 1986). Although *T. bragai* is considered to be a low pathogenic parasite, infection may determine clinical signs, such as apathy, weight loss and diarrhea, sometimes followed by death. The main necropsy findings are an increase in kidney volume, polycystic kidney of abnormal shape, a friable surface and yellowish brown coloration (Portugal et al. 1972, Mena et al. 1986). Microscopically, adults and eggs are found in the renal parenchyma, with dilation of the collecting ducts affecting kidney morphology (Portugal et al. 1972, Menezes et al. 2001, Mapeli et al. 2003, Pinto et al. 2004, Gomes et al. 2005). Cases of glomerulonephritis leading to chronic kidney failure and death have been described in species of Psittacidae (Luppi et al. 2007). The few studies on his-

topathological lesions indicate that the hosts and lesions associated with this parasite are not yet well established (Gomes et al. 2005).

This article reports the first record of *T. bragai* parasitizing peacocks (*Pavo cristatus*) and describes the macroscopic and microscopic findings associated with parasitism.

MATERIALS AND METHODS

A male and a female peacock (*Pavo cristatus* Linnaeus, 1758) about 14 years old were sent to the Avian and Swine Disease Laboratory of the Federal University of Lavras, Minas Gerais, Brazil, for necropsy and parasitological and histopathological evaluation. The organs were collected in buffered formalin, embedded in paraffin, cut into 5µm and stained with hematoxylin-eosin for histological exam. Tissue fragments were submitted to the anti-*Salmonella* spp. immunohistochemical technique. All organs were individually removed for macroscopic analysis and parasitological evaluation. For the trematode study, the kidneys were sectioned and placed in 9% saline solution. The organs were then transferred to a BOD chamber for 12h at 37°C. The parasites were collected with the aid of a brush and transferred to PBS1X solution at room temperature. Trematodes were placed on glass slides and slightly compressed with a cover slip, followed by the addition of alcohol-formalin-acetic acid solution for fixation. Slides with compressed parasites were kept under refrigeration for 12 hours. The fixed parasites were dehydrated in a series of solutions with an increasing concentration of alcohol and stained with carmine hydrochloride. Stained parasites were fixed on slides with resin for identification based on Travassos et al. (1969) and Kanev et al. (2002).

RESULTS

The macroscopic exam revealed discreet yellow spots on the liver tissue of both peacocks. The microscopic exam revealed an absence of significant findings in the liver. The immunohistochemical analysis for anti-*Salmonella* spp was negative. The histological sections of the kidney revealed parasites in the collecting ducts, which were markedly dilated with a thickened wall. Other findings included a mild inflammatory reaction in the wall of the ducts (but sometimes absent), flattening of lining epithelial cells and small, multifocal points of calcification around the collecting ducts. (Fig.1A-F). Sections of the liver also revealed a mild inflammatory reaction and multifocal points of calcification.

During the parasitological exam, a mean of 33 parasites were retrieved from the kidneys (36 parasites in the left kidney and 30 parasites in the right kidney). The microscopic exam revealed dorsally-ventrally flat trematodes with an elongated body of medium size (Mean: 1.5mm, SD: 0.5mm), well-developed sub terminal oral sucker, pharynx present, short esophagus, cecum with blind end, testes symmetrical, equatorial, irregular in shape or slightly lobed, partially overlapping the ceca, pre-ovarian and post ovarian extra-cecalvitelline fields, uterus very long, intercecal or sometimes overlapping the ceca and containing large quantities of eggs, and spines on the tegument (Fig.2A,B). The morphological findings and location of the parasites allowed the conclusive diagnosis of infection by *Tanaisia* (*Paratanaisia*) *bragai*.

Fig.1. Histological section a peacock (*Pavo cristatus*) kidney showing *Tanaisia (Paratanaisia) bragai*. (A) Accentuated dilation of collecting duct and mild inflammatory reaction around duct (arrows), HE, obj.10x. (B) Parasites (P) in interior of collecting duct. Observe the accentuated dilation of collecting duct, with intense peripheral inflammatory reaction (arrows) and associated with calcifications (C), HE, obj.4x. (C) Detail of metaplasia of the wall of the collecting duct with presence of parasite (P). Thickening of epithelial cells extending to the center of the duct (arrow) and mild peripheral inflammatory reaction (I). HE, obj.40x. (D) Collecting duct with parasite, cut reveals internal structures of parasite: ceca (C), testicles (T) and pre-vitelline spaces (arrows), with metaplasia of duct epithelial cells. HE, obj.10x. (E) Cross-section showing specimen of *T. bragai* in markedly dilated collecting duct, cut reveals oral sucker of parasite adhered to tubular epithelium. HE, obj.10x. (F) Specimen of *T. bragai* in markedly dilated collection duct, cut reveals oral sucker of parasite (arrow) adhered to tubular epithelium. HE, obj.20x.

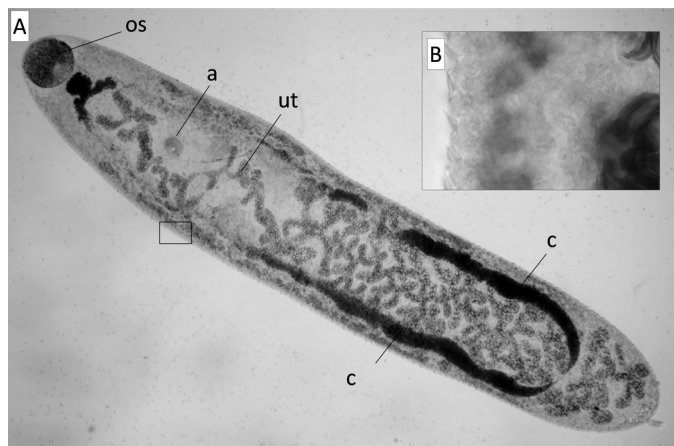
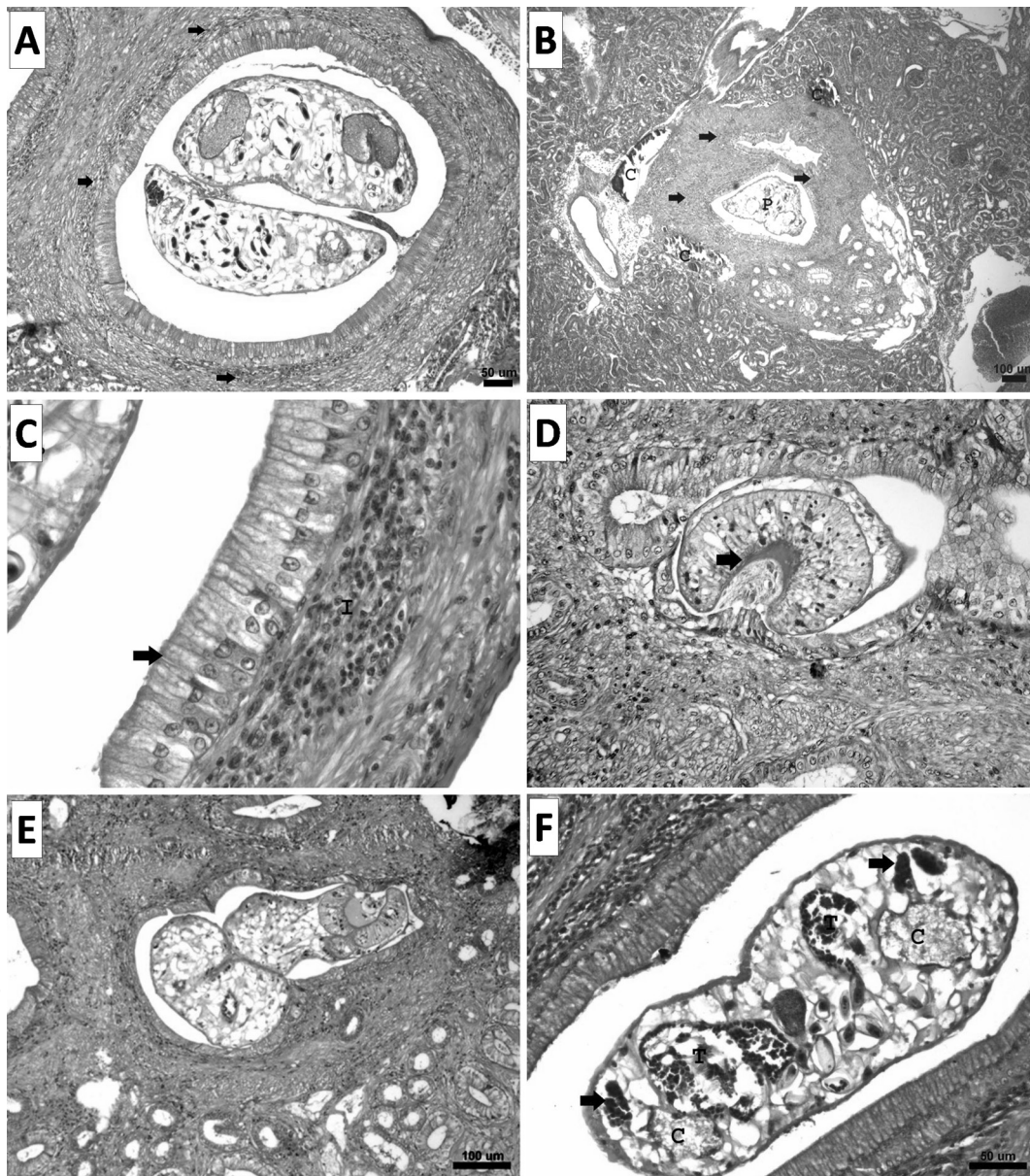


Fig.2. Adult specimen of *Tanaisia (Paratanaisia) bragai* retrieved from kidney of naturally infected peacock. (A) Fixed specimen showing intestinal ceca (c), uterus filled with eggs (ut), oral sucker (os) and acetabulum (a). (B) Tegument with spines.

DISCUSSION

The trematode *Tanaisia (Paratanaisia) bragai* is commonly found parasitizing different bird species in Brazil, but has not previously been described in peacocks. The morphometric findings of the specimens described in the present study are in agreement descriptions of this species in the literature (Menezes et al. 2001, Pinto et al. 2004).

Menezes et al. (2001) reported the presence of 142 trematodes in a single kidney. In the present study, the low parasite burden found in the infected bird, the absence of significant macroscopic findings and the discreet microscopic findings suggest that the species has low pathogenicity for peacocks, at least with a low parasite burden.

The microscopic findings may be considered mild in comparison to reports in other species, such as the pheasant, blue-winged macaw and ruddy ground dove (Gomes et al., 2005, Pinto et al., 2004, Luppi et al., 2007). The fin-

dings in the collecting ducts (thickening and dilation of the wall and mild inflammatory reaction) seem to be related to the mechanical action of the parasites related to the spines on the tegument. Hyperplasia of the duct epithelium and calcifications around the ducts has not been reported in other hosts, which may indicate old lesions that had healed (considering the age of the birds examined).

Nonspecific clinical signs of infection by *T. bragai* have been reported in birds with a high parasite burden (Greve, 1986, Mena et al. 1986, Mapeli et al. 2003). However, some authors state that the occurrence and severity of microscopic findings do not seem to be related to the parasite load (Pinto et al., 2004). These contradictory data underscore the need for further studies on the pathogenic potential of this species in different hosts.

This paper describes the first report of infection by *T. bragai* in peacocks and offers data of the lesions associated to this parasitism, although the degree of pathogenicity and parasite load may be considered mild. The present findings suggest the need for further diagnostic studies on the prevalence of this trematode in peacocks as well as pathologic studies for the determination of the potential pathogenicity of this parasite in this species of bird. Moreover, infected peacocks could serve as carriers of *T. bragai* to other bird species, thereby contributing to the epidemiology of the parasite.

Agradecimentos.- À Fundação de Amparo à Pesquisa do Estado de Minas Gerais (FAPEMIG), pelo auxílio financeiro à publicação da pesquisa.

REFERENCES

- Brandolini S.V.P.B., Amato S.B. & Pereira A.A. 1997. Relacionamento de *Tanaisia bragai* (Digenea, Eucotylidae) e seu hospedeiro intermediário, *Subulina octona* (Gastropoda, Subulinidae) sob condições experimentais. *Parasitologia* 21:109-113.
- Gomes D.C., Menezes R.C., Tortelly R. & Pinto R.M. 2005. Pathology and first occurrence of the kidney trematode *Paratanaisia bragai* (Santos, 1934) Freitas, 1959 (Digenea: Eucotylidae) in *Phasianus colchicus* L., 1758, from Brazil. *Mem. Inst. Oswaldo Cruz* 100:285-288.
- Greve J.H. 1986. Parasitic diseases, p.233-251. In: Fowler M.E. (Ed.), *Zoo and Wildlife Medicine*. W.B. Saunders, Philadelphia.
- Kanev I., Radev V. & Fried B. 2002. Family Eucotylidae, p.147-152. In: Gibson D.I., Jones A. & Bray R.A. (Eds), *Keys to the Trematoda*. CAB International and The Natural History Museum, London.
- Keller D.G. & Araujo J.L.B. 1992. Ciclo evolutivo de *Paratanaisia bragai* (Santos, 1934) (Trematoda, Eucotylidae) com novo hospedeiro intermediário no Brasil: *Leptinaria unilamellata* (D'Orbigny, 1835) (Gastropoda, Pulmonata, Subulinidae) em condições de laboratório. *Revta Bras. Parasitol. Vet.* 1:89-92.
- Luppi M.M., De Melo A.L., Motta R.O., Malta M.C., Gardiner C.H. & Santos R.L. 2007. Granulomatous nephritis in psittacines associated with parasitism by the trematode *Paratanaisia* spp. *Vet. Parasitol.* 31:363-366.
- Mapeli E.B., Nascimento A.A., Szabó M.P.J. & Tebaldi J.H. 2003. Infecções naturais por helmintos em perdizes (*Rhynchotus rufescens* Temminck, 1815) de cativeiro, no Município de Jaboticabal, estado de São Paulo. *Arqs Inst. Biológico, São Paulo*, 70:415-418.
- Mena R., Mendez M. & Aguirre R. 1986. Presencia em Cuba de la trematodiasis renal de la paloma domestica (*Columba livia domestica*) por *Tamerlania bragai* (Dos Santos, 1934). *Revta Cub. Cienc. Vet.* 17:25-28.
- Menezes R.C., Mattos Jr D.G. & Gomes D.C. 2001. Trematodes of free range reared guinea fowls (*Numida meleagris* Linnaeus, 1758) in the state of Rio de Janeiro, Brazil: morphology and pathology. *Avian Pathol.* 30:209-214.
- Pinto R.M., Menezes R.C. & Tortelly R. 2004. Systematic and pathologic study of *Paratanaisia bragai* (Santos, 1934) Freitas, 1959 (Digenea, Eucotylidae) infestation in ruddy ground dove *Columbina talpacoti* (Temminck, 1811). *Arq. Bras. Med. Vet. Zootec.* 56:472-479.
- Portugal M.A.S.C., Oliveira G.F., Fenerich F.L., Cappellaro C.E.M.P.M & Chiarelli V.1972. Ocorrência de *Paratanaisia bragai* (Santos, 1934) Freitas, 1959 (Trematoda: Eucotylidae), em pomba doméstica (*Columba livia domestica*). *Arq. Inst. Biológico, São Paulo*, 39:189-194.
- Travassos L., Freitas J.F.T. & Kohn A. 1969. Trematódeos do Brasil. *Mem. Inst. Oswaldo Cruz* 67:1-886.